



Study of the effect of ginseng on testicular function after immobilization stress in rat

Navid Pashaeian¹, SeyedEsmail Safavi^{2*}, Mehrdad Neshat Gharamaleki³

¹*Department of Clinical sciences, College of Veterinary Medicine, Tabriz Branch, Islamic Azad University, Tabriz, Iran*

²*Department of Basic Sciences, College of Veterinary Medicine, Tabriz Branch, Islamic Azad University, Tabriz, Iran*

³*Department of Clinical sciences, College of Veterinary Medicine, Tabriz Branch, Islamic Azad University, Tabriz, Iran*

Key words: Ginseng, Rat, Immobility stress, Testis, Histomorphology, Testosterone.

<http://dx.doi.org/10.12692/ijb/6.4.184-191>

Article published on February 28, 2015

Abstract

Stress can be mental or physical, although in the context of this article the focus will be physical stress. In this research we studied effects of ginseng under immobility stress on some testicular tissues and some hormones of male rats. In this experiment, the first and second groups were transferred daily into the Restrainer and were under Immobility stress for 2 hours per day during 15 days. For ginseng group ginseng 500mg/kg was given daily after immobility stress. The treatment group and control group were given water instead of ginseng by gavage each day. After morphology and histomorphological study of testis tissue and range of serum testosterone analysis, results discussed. Our results show that using ginseng under stress cases plays protective role of testis tissues. Present study has improved ginseng anti stress properties.

* **Corresponding Author:** Seyed Esmail Safavi

Introduction

The ginseng root has been used for over 2000 years, in the belief that it is a panacea and promotes longevity. Ginseng (*Panax. sp.*) is valuable in Chinese medicine and plays an important role in folk medicine in East Asia (Khakzadihe *et al.*, 2014; Attele *et al.*, 1999). Ginseng glycopeptides have pharmacological effects, e.g., immunomodulatory, anti-tumor, anti-ulcer and hypoglycemic activities (Saleh, 2012; Takahashi *et al.*, 1992). The pharmacological effects of ginseng have been demonstrated in the central nervous system, the cardiovascular system, as well as the endocrine and immune systems (Khakzadihe *et al.*, 2014; Shin *et al.*, 2006; Gillis, 1997). In addition, ginseng and its constituents have been ascribed anti neoplastic, anti stress, and antioxidant activity (Gillis, 1997; Benishin, 1992; Yoshikava *et al.*, 1998). Stress is a ubiquitous condition that affects all animals. Stress can be mental or physical, although in the context of this article the focus will be physical stress. The testes produce the male gametes and the male sexual hormones (androgens). The term spermatogenesis describes and includes all the processes involved in the production of gametes, whereas steroidogenesis refers to the enzymatic reactions leading to the production of male steroid hormones. Spermatogenesis and steroidogenesis take place in two compartments morphologically and functionally distinguishable from each other. There were a lot of researches about ginseng effects under stress cases, for example in research conducted by Khakzadihe *et al.* (2014) effects of ginseng under immobility stress studied also in other study that conducted by Hendawy *et al.* antioxidant effects of ginseng studied on testis tissues that treated with chlorpyrifos. But histomorphological effects of ginseng under immobility stress haven't been studied yet so we decided to investigate the effects of ginseng by histomorphology method. In this research we studied effects of ginseng under immobility stress on some testicular tissues and testosterone hormone of male rats.

Material and methods

Animal breeding

For this study, 24 adult male rats (Wistar rats) were randomly selected and weighed (The average body weight 180 to 220 gram). Then the rats were divided into three groups of 8 rats so that the weighted average of the two groups showed no significant differences. During the entire period, feeding was performed on the ad libitum basis. The consumed water was the city tap water which was re-refined using carbon and sand filters. The environment was exposed to 12-hour lighting and 12-hour dark during the experiment for each group. The room temperature was 22±2 Degrees Celsius during the experimental period. In this experiment, the first (group Treatment) and second (group Ginseng treatment) groups were transferred daily into the Restrainer and were under Immobility stress for 2 hours per day during 15 days. For ginseng group ginseng 500mg/kg (Ginsin capsule, each capsule contains: Ginseng rhizoma 250mg equivalent to 7mg Ginsenosides as Rg1, produced by Goldaru) was given daily after immobility stress (the drug was given by gavage). The treatment group and control group were given water instead of ginseng by gavage each day.

Tissue sampling and analysis

After 15 days, Tissue samples were taken on the 15th day from groups. For this level of our study we were used 10% formalin for fixation. After 20 days of fixation tissue samples prepared by staining. For this research we were used H&E method for tissue staining. Tissue samples studied under microscope by 10x lens. After cell counting, obtained number was multiplied by coefficients so the results were obtained in micrometers (µm). In this research we were studied diameter of seminiferous tubules, thickness of the epithelium of seminiferous tubules, interstitial tissue thickness and thickness of connective capsule. For spermatogenesis Evaluation, we were studied tubule differentiated index (TDI), spermiogenesis index and repopulation index. For TDI calculation, Percentage of seminiferous tubules that includes three or more than three Spermatogenic cells differentiated from A Spermatogonial cells calculated that these cells includes Intermediate spermatogonia, Spermatogonia type B, Spermatocytes and

Spermatids. For each testis, TDI calculation at least 200 cross sections of somniferous tubules were studied and counted. For Repopulation Index calculation, Active Spermatogonia compared to inactive Spermatogonia in somniferous tubules were calculated. For this, 200 cross sections of somniferous tubules were studied. For Spermogenesis index calculation, ratio of seminiferous tubules containing sperm to without sperm were calculated and counted in 200 cross sections.

Blood sampling and serum analysis

After 15 days, blood samples were taken on the 15th day from groups. The blood was added into the serum tube manufactured by Euro Tube[®] Company. After clotting, the blood was centrifuged with the speed of 3000 rpm for 10 minutes and the serum was removed. For testosterone analyzing we were used Competitive ELISA method.

Statistical Analysis

All raw data of this experiment was investigated by SPSS software version 15.00. The ANOVA and TUKEY HSD tests were used to analyze the data. Data

with 5% level ($p < 0.05$) of significance were considered.

Results

Testicular tissue Morphological and Histomorphological results

In control group, the diameter of seminiferous tubules is normal. Tubule wall thickness is thick and sperm observed in seminiferous tubules, interstitial tissue thickness is low and most spermatogenesis cell lines observed (fig 1-1). In under stress group reducing the diameter of the seminiferous tubules were identified and a number of seminiferous tubules are deformed, wall thickness of tubules reduced and small numbers of sperm in the central cavity of the tube can be seen (fig1-2). In some other under stress group, exudative fibrin exudates observed. Also Separation and detachment of spermatozoid cells from the basement membrane of seminiferous tubules observed (fig 1-3). In ginseng treatment group, increasing the diameter of the seminiferous tubules, increase the tubule wall thickness and reducing interstitial tissue observed. The number of seminiferous tubules had sperm and some of them had not (fig 1-4).

Table 1-1. Histomorphological parameters between groups (mean±Std).

	Connective tissue capsule diameter	Interstitial tissue thickness	Epithelium thickness	Seminiferous tubule diameter
Control	20.91±1.15 ^a	14.7±1.08 ^a	92.05±0.12 ^a	22159±0.42 ^a
Ginseng treatment	22.98±0.14 ^a	22.18±1.42 ^b	81.09±0.04 ^b	216.54±0.52 ^b
stress	20.4±0.98 ^a	31.78±1.19 ^c	61.2±0.36 ^c	177.48±0.81 ^c

Epididymal tissue Morphological and Histomorphological results

In control group, a large number of sperm in the epididymis tube sections can be seen. All tubes compactly filled testicular secretions and sperm that to be occupied (1-5). In under stress group, many sections of epididymal tail tubes had no sperm or had Low sperm which is a marker of impaired sperm production (1-6). In ginseng treatment group, greater number of tubes epididymis had sperm (1-7).

The histomorphological results have been placed in 1-

1 and 1-2 tables also Testosterone concentrations level is in 1-3 table. Data with same letter (a, b and c) has no significant differences ($P < 0.05$).

Discussion

Ginseng (*Panax ginseng*), one of the most widely studied medicinal herbs, contains saponin, phenolic compounds, polyacetylene, alkaloids, and polysaccharides (Attele *et al.*, 1999, Shin *et al.*, 1990). Maltol, a unique substance of red ginseng produced during the manufacture of red ginseng from fresh ginseng, is known to have potent antioxidant activity

(Shin *et al.*, 1990). The most important cells of Interstitial Compartment are the Leydig cells. These cells are the source of testicular testosterone and of insulin-like factor 3 (INSL3). Aside from Leydig cells, the interstitial compartment also contains immune cells, blood and lymph vessels, nerves, fibroblasts and loose connective tissue (Narula *et al.*, 2002). Spermatogenesis takes place in the tubular compartment. This compartment represents about 60–80% of the total testicular volume. It contains the germ cells and two different types of somatic cells, the peritubular cells and the Sertoli cells. The testis is divided by septa of connective tissue into about 250–300 lobules. Spermatogenesis starts with the division of stem cells and ends with the formation of mature

sperm (Shono, 2007; Shetty *et al.*, 1998). The various germ cells are arranged in typical cellular associations within the seminiferous tubules known as spermatogenic stages. Testosterone is the main secretory product of the testis, along with 5 α -dihydrotestosterone (DHT), androsterone, androstenedione, 17-hydroxyprogesterone, progesterone and pregnenolone. The role of androsterone, progesterone and 17-hydroxyprogesterone in the testis is unknown but progesterone receptors have been found in some peritubular cells and on spermatozoa (Luetjens *et al.*, 2006; Modi *et al.*, 2007). The half-life of testosterone in plasma is only about 12 min.

Table 1-2. RI, SPI and TDI parameters between groups (mean \pm Std).

	R.I	S.P.I	T.D.I
Control	98.9 \pm 0.03 ^a	93.7 \pm 0.08 ^a	94 \pm 0.98 ^a
Ginseng treatment	84.8 \pm 0.02 ^b	79.7 \pm 0.02 ^b	80.6 \pm 1.03 ^b
stress	66.9 \pm 0.01 ^c	60.1 \pm 0.01 ^c	64.4 \pm 1.07 ^c

In a research conducted with Knol (1991) the stress and the endocrine hypothalamus-pituitary-testis system reviewed. Knol reported that stressor-induced depression of the HPT system occurred through interaction with the HPA system at three levels (hypothalamus, pituitary, testis), and was mediated by both EOP and corticosteroids. In subordinate

males, the longstanding activation of the HPA system results in down-regulation of the corticosteroid recaptured at the pituitary level and higher in the brain. Knol results in a decreased sensitivity of the feedback system to corticosteroids and, consequently, in hypersecretion throughout the HPA system (Knol, 1991).

Table 1-3. Testosterone concentrations between groups (mean \pm Std).

Testosterone concentrations	
Control	2.8 \pm 0.20 ^a
Ginseng treatment	4.82 \pm 0.17 ^b
Stress	1.61 \pm 0.05 ^c

In other research conducted by Diab *et al.* (2012) Antioxidant Role of both Propolis and Ginseng against Neurotoxicity of Chlorpyrifos and Profenofos in Male Rats were studied. From the obtained results, they reported that both organophosphorous insecticides either Chlorpyrifos or profenofos have very dangerous and toxic effects, since they showed many side effects represented by high level of

antioxidant enzymes and decreasing acetylcholinesterase enzyme. Moreover, the damage in tissues of brain. So they recommend the use of the combination of propolis and ginseng which is known as antioxidants compounds in order to ameliorate the possible side effects caused by insecticides that they exposed to them to avoid the proven hazardous effect of insecticides on biochemical parameters and to

overcome the side effects of both Chlorpyrifos and profenofos on liver (Diab *et al.*, 2012).

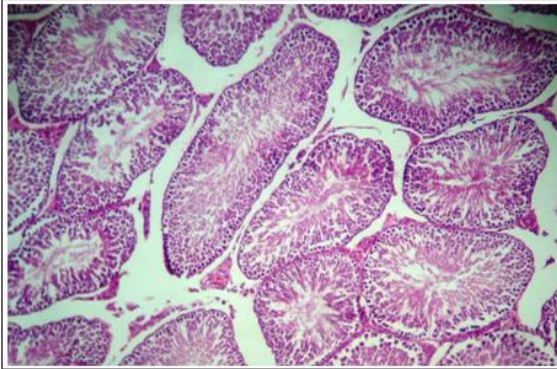


Fig. 1-1. Testicular tissue of control group.

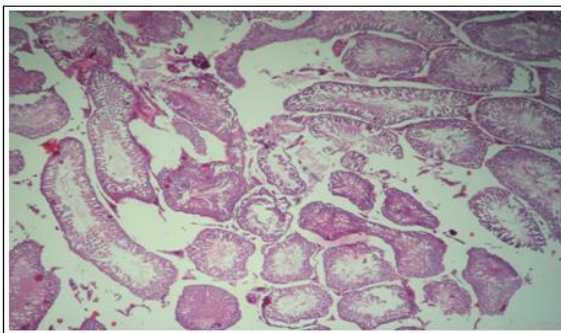


Fig. 1-2. Testicular tissue of under stress group.

In Ismail Mohamed *et al* study (2007) cholinesterase (ChE) activity in seven brain regions (cerebral cortex, thalamus, hypothalamus, midbrain, cerebellum, pons and medulla oblongata), heart, liver and serum of adult male albino rats were determined following diabetes induction by a single subcutaneous injection of alloxan monohydrate (120 mg/kg body weight), oral administration of Panax ginseng extract (100 mg/kg body weight) for 12 consecutive days and the coadministration of both treatments. The enzyme activity was estimated after 2, 4, 8 and 12 days of alloxan and or Panax ginseng administration. Concomitant variation in blood glucose level and body weight of treated rats were also recorded. They reported ginseng may possess a significant anti-hyperglycemic effect and may prove to be beneficial in improving the management of diabetes. Besides, it may have selective positive effect on the cholinergic system (Ismail Mohamed *et al* 2007).

In a Lin *et al* resarches (2014) time-course changes of steroidogenic gene expression and steroidogenesis

of rat leydig cells after acute immobilization stress studied. They reported the acute immobilization led to the elevated CORT levels as early as 0.5 h followed by the reduced testosterone levels 3 h under immobilization stress. High CORT level may result in binding to NR3C1, which targets cholesterol transport genes (*Scarb1* and *Star*) and steroidogenic enzyme (*Cyp17a1*) genes, to suppress their expressions, which are more sensitive to suppression by acute stress (Lin *et al.*, 2014).

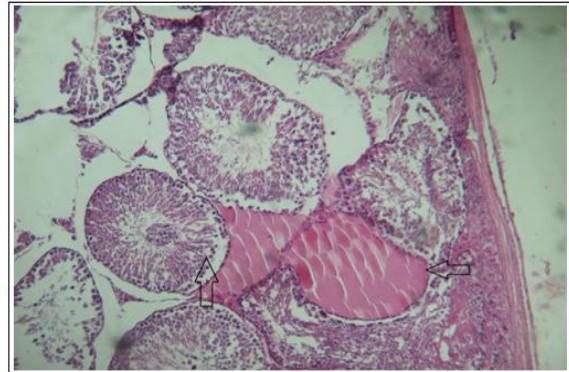


Fig. 1-3. Testicular tissue of under stress group.

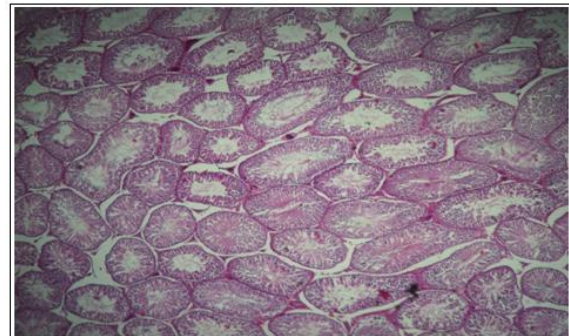


Fig. 1-4. testicular tissue of ginseng treatment group.

In other research conducted by Demura *et al.* (1989) effect of immobilization stress on testosterone and inhibin in male rats were studied. These findings indicate that in male rat immobilization stress induced dissociation in LH and FSH responses, and decreased testosterone while inhibin remained unaffected. In their study testicular weights didn't have significant differences between groups (Demura *et al.*, 1989). Our result corresponded with Demura studies.

In other similar study that designed by Joo *et al.* (2006) effect of long-term immobilization stress on spermatogenesis and testosterone production

studied. The aim of Joo *et al* study was to investigate the effects of long-term immobilization stress on spermatogenesis and testosterone production in a rat model. The results showed the serum concentration of corticosterone was significantly increased; whereas, the serum concentrations of LH and testosterone were decreased. Joo *et al.* results suggest that the exposure to long-term immobilization impairs spermatogenesis and androgenic testicular functions in rats (Joo *et al.*, 2006). Our result corresponded with Joo *et al.* studies.

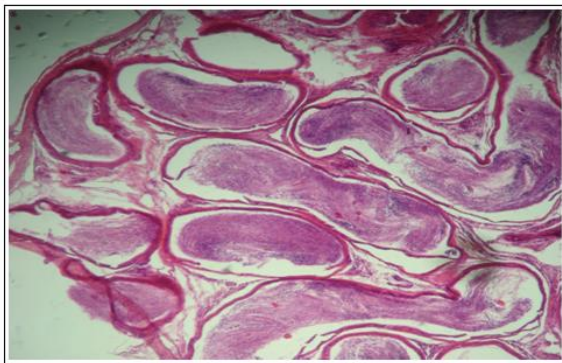


Fig. 1-5. Epididymis tissue of control group.

In other study, acute immobilization stress disrupts testicular steroidogenesis in adult male rats by inhibiting the activities of 17 α -Hydroxylase and 17, 20-Lyase without affecting the binding of LH/hCG receptors had been studied by Edward *et al.* (1994). In Edward *et al.* research, immobilization for 3 hours dramatically reduced plasma and testicular levels of T, but the binding characteristics of testicular LH/hCG receptors cells were not affected. The resultant reduction of T production during 3 hours of immobilization appears to be related to a loss of enzyme protein or to noncompetitive inhibition of the activities of 17 α -hydroxylase and 17, 20-lyase. Additional experiments are necessary to elucidate the mechanisms by which acute immobilization stress inhibits the testicular activities of 17 α -hydroxylase and 17, 20-lyase (Edward *et al.*, 1994).

In Dong *et al* research (2004), rapid glucocorticoid mediation of suppressed testosterone biosynthesis in male mice subjected to immobilization stress, studied. In this research IMO stress was found to suppress androgen secretion in mice. LH levels were

unchanged, but T levels declined in the presence of elevated serum CORT concentrations. Local intratesticular administration of RU486 partially reversed the IMO stress-induced decrease in T levels, confirming that glucocorticoid and its receptor are involved in steroidogenic suppression. This indicates that glucocorticoid-mediated inhibition of Leydig cell steroidogenesis is a direct action at the testicular level. Suppression of intracellular cAMP levels in Leydig cells is implicated in the rapid response pathway induced by IMO stress (Dong *et al.*, 2004).

In a research designed by Kim *et al.* (2010), effect of Korean red ginseng on testicular tissue injury after torsion and detorsion studied. Their study designed to determine whether KRG could protect against dysfunction and oxidative stress induced by torsion-detorsion injury in rat testis. The results of Kim *et al* study demonstrated that I-R leads to testis dysfunction, as well as the induction of ROS. Also demonstrated that KRG recovered the testis dysfunction caused by ischemia and subsequent reperfusion in the rat testis through the suppression of superoxide production (Kim *et al.*, 2010).

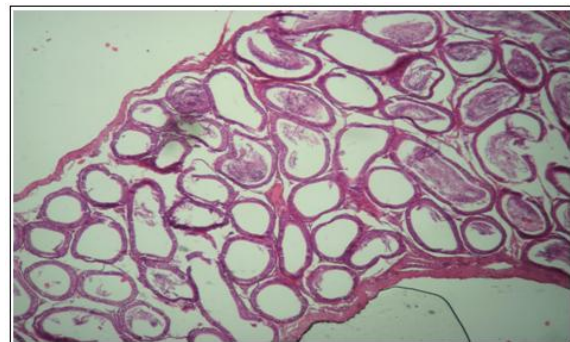


Fig. 1-6. Epididymis tissue of stress group.

In Khakzadihe *et al.* (2014) research, effects of ginseng under immobility stress on phosphorus, magnesium and ALP of blood serum on male rats studied. In Khakzadihe *et al.* study, 24 adult male rats were randomly selected. Rats were divided into three groups of 8 rats. Treatment and Ginseng treatment groups were transferred daily into the Restraint and were under Immobility stress for 2 hours per day during 15 days. For ginseng group ginseng 500mg/kg (Ginsin capsule) was given daily after immobility stress. In their study there was no significant difference between all groups on magnesium and ALP

levels. There was significant difference between treatment and ginseng treatment groups on serum phosphate also there was significant difference between treatment and control groups on phosphate level.

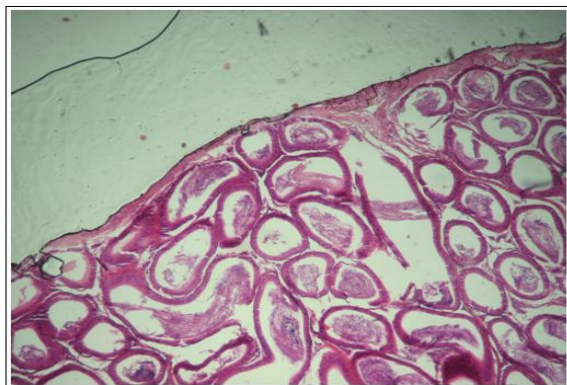


Fig. 1-7. Epididymis tissue of ginseng treatment group.

In summary our results show that using ginseng under stress cases plays protective role of testis tissues. Present study has improved ginseng anti stress properties. Other scientists with same similar subjects have similar results of presented study.

References

- Attele AS, Wu JA, Yuan CS.** 1999. Ginseng pharmacology: multiple constituents and multiple actions, *Biochem Pharmacol*, **58**, 1685-169. [http://dx.doi.org/10.1016/S0006-2952\(99\)00212-9](http://dx.doi.org/10.1016/S0006-2952(99)00212-9)
- Benishin CG.** 1992. Actions of ginsenoside Rb1 on choline uptake in central cholinergic nerve endings, *Neurochem Int.* **21**, 1-5. [http://dx.doi.org/10.1016/0197-0186\(92\)90061-u](http://dx.doi.org/10.1016/0197-0186(92)90061-u)
- Demura R, Suzuki T, Nakamura S, Komatsu H, Odagiri E, Demura H.** 1989. Effect of Immobilization Stress on Testosterone and Inhibin in Male Rats, *Journal of Andrology* **10**, 210-213.
- Diab AA, Abd El-Aziz EA, Hendawy AA, Zahra MH, Hamza RZ.** 2012. Antioxidant Role of both Propolis and Ginseng against Neurotoxicity of Chlorpyrifos and Profenofos in Male Rats, *Life Science Journal*, **9(3)**, 987-1008. <http://dx.doi.org/10.1016/j.pestbp.2012.04.002>
- Dong Q, Salva A, Sottas C, Niu E, Holmes M, Hardy MP.** 2004. Rapid Glucocorticoid Mediation of Suppressed Testosterone Biosynthesis in Male Mice Subjected to Immobilization Stress, *Journal of Andrology*, **25(6)**, 973-981.
- Edward TO, Taylor MF, Bhattacharyya AK, Collins DC, Mann DR.** 1994. Acute Immobilization Stress Disrupts Testicular Steroidogenesis in Adult Male Rats by Inhibiting the Activities of 17 α -Hydroxylase and 17, 20-Lyase Without Affecting the Binding of LH/hCG Receptors, *Journal of Andrology*, **15(4)**, 302-308.
- Gillis CN.** 1997. Panax ginseng pharmacology: A nitric oxide link, *Biochem Pharmacol* **54**, 1-8. [http://dx.doi.org/10.1016/S0006-2952\(97\)00193-7](http://dx.doi.org/10.1016/S0006-2952(97)00193-7)
- Ismail Mohamed M, Aly MS, Abdel Rahman T, Mahmoud SM.** 2007. Effect of panax ginseng on the activity of cholinesterase in different tissues of experimental-induced diabetes in rats, *The Egyptian society of toxicology* **3**, 95-106.
- Joo JS, Park K, Ahn KY, Park YT.** 2006. The Effect of Long-term Immobilization Stress on Spermatogenesis and Testosterone Production, *Korean Journal of Urology*, **47**, 1197-1203. <http://dx.doi.org/10.4111/kju.2006.47.11.1197>
- Khakzadihe M, Pashaeian N, Daghighian R, Rasoulifard M, Chardoli A, Hajikhani S, Naser Ardrizi N, Vazifehdust S.** 2014. study effects of ginseng under immobility stress on phosphor, magnesium and ALP of blood serum on male rats, *Biosciences Biotechnology Research Asia* **11(2)**, 723-726. <http://dx.doi.org/10.13005/bbra/1327>
- Kim Y, Kim G, Shin J, Kim K, Lim J.** 2010. Effect of Korean Red Ginseng on Testicular Tissue Injury after Torsion and Detorsion, *Korean Journal of Urology* **51**, 794-799. <http://dx.doi.org/10.4111/kju.2010.51.11.794>

- Knol BW** (1991) Stress and the endocrine hypothalamus-pituitary-testis system: A review, *The Veterinary Quarterly*, **13**(2).
<http://dx.doi.org/10.1080/01652176.1991.9694292>
- Lin H, Yuan K, Zhou H, Bu T, Su H, Liu S, Zhu Q, Wang Y, Hu Y, Shan Y, Lian Q, Wu X, Ge R.** 2014. Time-Course Changes of Steroidogenic Gene Expression and Steroidogenesis of Rat Leydig Cells after Acute Immobilization Stress. *Molecular Sciences* **15**, 21028-21044.
<http://dx.doi.org/10.3390/ijms151121028>
- Luetjens CM, Didolkar A, Kliesch S, Paulus W, Jeibmann A, Böcker W, Nieschlag E, Simoni M.** 2006. Tissue expression of the nuclear progesterone receptor in male non-human primates and men, *Journal of Endocrinology*, **189**, 529–539.
- Modi DN, Shah C, Puri CP.** 2007. Non-genomic membrane progesterone receptors on human spermatozoa. *Soc Reprod Fertil, Suppl* **63**, 515–529.
- Narula A, Gu YQ, O'Donnell L, Stanton PG, Robertson DM, McLachlan RI, Bremner WJ.** 2002. Variability in sperm suppression during testosterone administration to adult monkeys is related to follicle stimulating hormone suppression and not to intratesticular androgens, *Journal of Clinical Endocrinology Metabolism*, **87**, 3399–3406.
<http://dx.doi.org/10.1210/jcem.87.7.8681>
- Saleh AAS.** 2012. Effects of taurine and/or ginseng and their mixture on lipid profile and some parameters indicative of myocardial status in streptozotocin-diabetic rats, *The Journal of Basic & Applied Zoology* **65**, 267-273.
<http://dx.doi.org/10.1016/j.jobaz.2011.12.001>
- Shetty G, Krishnamurthy H, Krishnamurthy HN, Bhatnagar AS, Moudgal NR.** 1998. Effect of long-term treatment with aromatase inhibitor on testicular function of adult male bonnet monkeys (*M. radiata*), *Steroids* **63**, 414–420.
[http://dx.doi.org/10.1016/S0039-128X\(98\)00042-7](http://dx.doi.org/10.1016/S0039-128X(98)00042-7)
- Shin JG, Park JW, Pyo JK, Kim MS, Chung MH.** 1990. Protective effects of a ginseng component, maltol (2-methyl-3-hydroxy-4-pyrone), against tissue damages induced by oxygen radicals, *Korean Journal of Ginseng Science* **14**, 187-190.
- Shono T.** 2007. Molecular and anatomical studies of testicular descent, *Hinyokika Kyo* **53**, 505–508.
- Takahashi M, Tokuyama S, Kaneto H.** 1992. Anti-stress effect of ginseng on the inhibition of the development of morphine tolerance in stressed mice, *The Japanese Journal of Pharmacology* **59**, 399-404.
<http://dx.doi.org/10.1254/jjp.59.399>
- Yoshikawa M, Murakami T, Yashiro K, Yamahara J, Matsuda H, Sadoh R, Tanaka O.** 1998. Bioactive saponins and glycosides. XI. Structures of new dammarane-type triterpene oligoglycosides, quinquenosides I, II, III, IV, and V, from American Ginseng, the roots of *Panax quinquefolium* L. *Chem Pharm Bull (Tokyo)* **46**, 647-654.
<http://dx.doi.org/10.1248/cpb.46.647>